

Influence of Thin Mucosal Tissues on Crestal Bone Stability Around Implants With Platform Switching: A 1-year Pilot Study

*Tomas Linkevicius, DDS, Dip Pros, PhD,**

Peteris Apse, Prof, DDS, Dip Pros, MSc (Toronto), Dr hab Med (Latvia),†

Simonas Grybauskas, DDS, MOS, RCSEd, PhD,‡ and

Algirdas Puisys, DDS§

Purpose: The aim of this pilot study was to determine what effect thin mucosal tissues can have on crestal bone stability around implants with platform switching.

Materials and Methods: Twelve 2-piece implants, consisting of 6 implants with horizontally matching implant-abutment connection (control) and 6 implants with platform switching (test) were placed in 4 patients. The mean age of the patients was 43 years (range, 37 to 56 yrs). Mucosal tissue thickness at implant sites was measured to be 2 mm or less. Implants were restored with 5 splinted crowns and single 3-unit fixed partial denture. Intraoral radiographs were obtained and crestal bone changes were measured at implant placement and after a 1-year follow-up post-treatment. The statistical significance level was set to P less than .05.

Results: Bone loss around the test implants was 1.81 ± 0.39 mm on the mesial site and 1.70 ± 0.35 mm on the distal aspect. Control implants overcame marginal bone resorption equaling 1.60 ± 0.46 mm on the mesial site and 1.76 ± 0.45 mm on distal measurement. No statistically significant difference was found between control and test implants either mesially ($F_{[1,10]} = 0.746$; $P = .408$) or distally ($F_{[1,10]} = 0.080$; $P = .783$).

Conclusion: Within the limitations of this pilot study it can be concluded that implants with platform switching did not preserve crestal bone better in comparison with implants with traditional implant-abutment connection if, at the time of implant placement, thin mucosal tissues were present.

© 2010 American Association of Oral and Maxillofacial Surgeons

J Oral Maxillofac Surg xx:xxx, 2010

Currently, dental implants with platform switching are considered to represent the newest concepts in avoiding crestal bone remodeling. It seems that the use of abutments with reduced diameter in relation to the implant platform can greatly reduce crestal bone

loss to far less than 1.5 mm, a reference point of successful implant treatment after 1 year of loading, proposed by Albrektsson et al.¹ Indeed, a number of retrospective studies reported minimal amounts of bone loss around implants with horizontally non-matching connection, reaching 0.60 mm after 4 years of loading and 0.70 mm after a follow-up of 7.5 years.^{2,3} Several controlled clinical trials have shown that implants with platform switching had significantly less bone resorption compared with traditional matching implant-abutment connection.^{4,6} These statements can also be supported by data from animal and human histological studies indicating the superiority of modified implant-abutment interface to traditional connection.^{7,8}

From a technical point of view, platform switching is a modification of implant-abutment micro-gap, which is found to be one of the major factors respon-

*Assistant Professor, Institute of Odontology, Vilnius University, Vilnius, Lithuania.

†Professor, Department of Prosthodontics, Riga Stradins University, Riga, Latvia.

‡Private Practice, Vilnius, Lithuania.

§Private Practice, Vilnius, Lithuania.

Address correspondence and reprint requests to Dr Linkevicius: Institute of Odontology, Vilnius University, Zalgiris str 115/117, LT-08217, Vilnius, Lithuania; e-mail: linktomo@gmail.com

© 2010 American Association of Oral and Maxillofacial Surgeons
0278-2391/10/xx0x0\$36.00/0

doi:10.1016/j.joms.2009.08.018

sible for bone remodeling in the apical direction.⁹⁻¹³ However, other factors, such as occlusal loading,¹⁴ polished implant neck,^{15,16} or mucosal tissue thickness¹⁷ have been shown to take part in the etiology of crestal bone loss as well. Soft tissue thickness was brought up as a factor by Berglundh and Lindhe¹⁷ in an animal study that showed that thin mucosal tissues can cause marginal bone resorption during the formation of biological width around implants. Recently, a clinical controlled study showed that if mucosal tissue thickness is 2 mm or less at the time of implant placement, even supracrestally positioned implants experience bone loss during the first year of function. Conversely, implants installed in thick tissues were associated with statistically significantly less bone loss.¹⁸ Thus, it seems that the thickness of mucosa covering the edentulous alveolar ridge before implantation is very important for subsequent stability of peri-implant crestal bone. However, its influence on implants with horizontally altered micro-gap is unknown.

Therefore, the aim of this pilot study was to determine what effects thin mucosal tissues can have on crestal bone stability around implants with platform switching. The null hypothesis was formulated that implants with platform switching would be associated with less crestal bone loss compared with implants with traditional interface.

Materials and Methods

PATIENTS

The study subjects were selected among partially edentulous patients who attended Vilnius Implantology Center (Vilnius, Lithuania) for implant treatment. Inclusion criteria were as follows: 1) thin mucosal tissues (2 mm or less), covering edentulous alveolar ridge; 2) patient age 18 years or more; 3) fully healed bone sites (at least 6 months after tooth extraction); 4) no bone augmentation procedures before and during implant placement; 5) edentulous gap for at least 2 implants in any region of the mouth with minimum 3-mm distance in between and minimum 1-mm range from adjacent tooth/teeth; 6) no medical contraindication for implant surgery; and 7) signed informed consent for participation and permission to use obtained data for research purposes. Patients were excluded if they did not meet requirements listed above and also had the following: 1) poor oral hygiene; 2) symptoms or history of periodontitis or peri-implantitis treatment; 3) poor cooperation relative to requirements for the study; 4) smoking; 5) alveolar ridges with bone defects at implantation sites; or 6) inadequate primary stability of implant, precluding healing abutment connection at the time of surgery.

The final patient sample included 4 patients (3 female and 1 male), who received 12 2-piece implants

in total, 6 implants with horizontally matching implant-abutment connection, and 6 implants with platform switching. The mean age of the patients was 43 years (range, 37 to 56 yrs).

IMPLANT PLACEMENT

Implants with platform switching modification (Prevail; 3i Biomet, Palm Beach Gardens, FL) were assigned as a test group and implants with horizontally matching implant-abutment connection (Prodigy; BioHorizons, Birmingham, AL) formed a control group (Figs 1, 2).

All patients received a prophylactic dose of antibiotics of 2 g amoxicillin (Ospamox; Biochemie, Kundl, Austria) 1 hour before the surgery. After the administration of 4% articaine solution (Ubistesin; 3 mol/L, 3M/ESPE, St Paul, MN) for local anesthesia, a midcrestal incision on the center of the edentulous ridge was performed. The flap was raised in 2 stages as follows. 1) The buccal flap was raised and the mucosal thickness of the unseparated lingual flap was measured with 1-mm marked periodontal probe (Hu-Friedy, Chicago, IL) at the bone crest in the center of future implant placement (Fig 3). This ensured direct visibility of gingival thickness measurement. 2) The lingual flap was raised to expose the implant site.

The osteotomy site was measured to allow a minimum 3-mm distance between the 2 implants, 1-mm range from adjacent tooth/teeth, and 1-mm space between buccal and lingual/palatal crest of the alveolar ridge and implant. Implants of different diameter



FIGURE 1. Test implant with platform switching.

Linkevicius et al. Crestal Bone Stability Around Implants. *J Oral Maxillofac Surg* 2010.

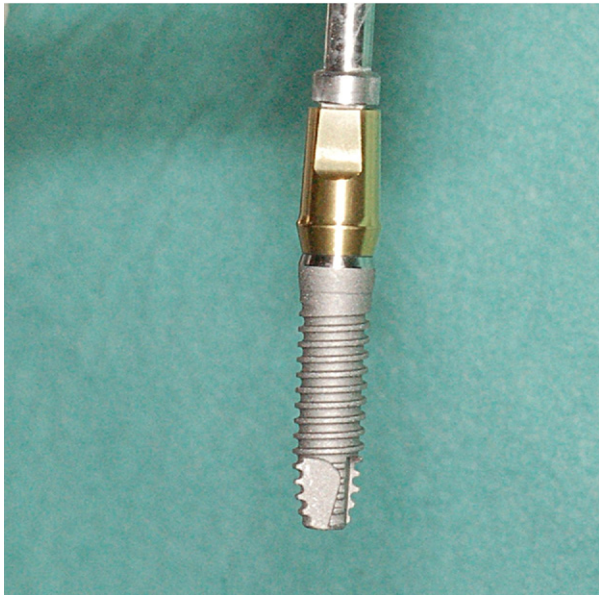


FIGURE 2. Control implant with traditional implant-abutment connection.

Linkevicius et al. Crestal Bone Stability Around Implants. J Oral Maxillofac Surg 2010.

(3.5 and 4.0) were placed in the control group according to the clinical situation. Test group implants were of 4.1-mm diameter (Fig 4). After implant placement, healing abutments were connected and 5/0 interrupted sutures (Polysorb; USS-DG, Norwalk, CT) were placed. Flaps were approximated without tension and sutured without leaving gaps (Fig 5). Patients were instructed to rinse the operated site with 0.12% chlorhexidine-digluconate (Fresenius Kabi, Norge, AS, Norway) solution twice a day for a week. For pain control, patients were prescribed 400 mg of ibuprofen (Ibumax; Vitabalans Oy, Helsinki, Finland) to be taken as needed. Patients were advised to minimize trauma to the site without introduction of a special

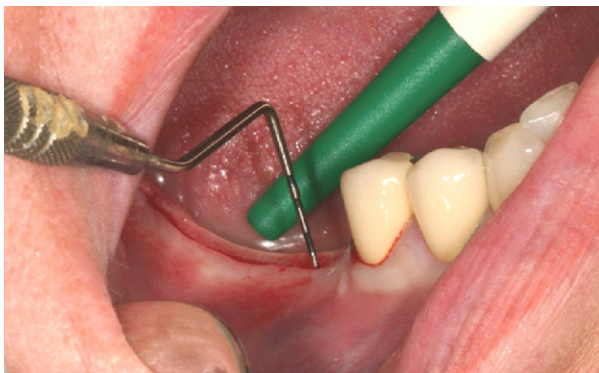

FIGURE 3. Measurement of mucosal tissue thickness before implant placement.

Linkevicius et al. Crestal Bone Stability Around Implants. J Oral Maxillofac Surg 2010.

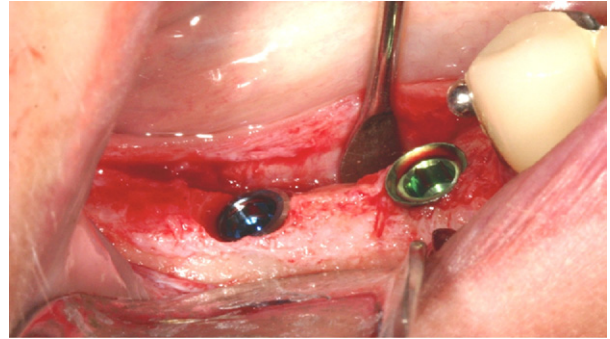


FIGURE 4. Crestal position of test implant (left) and control implant (right).

Linkevicius et al. Crestal Bone Stability Around Implants. J Oral Maxillofac Surg 2010.

diet. The sutures were removed 7 to 10 days after the surgery. Patients were advised to clean healing abutments with a very soft toothbrush.

RESTORATIVE PROCEDURES

Based on conventional healing protocol, prosthetic procedures were initiated after 2 months of healing in the lower jaw and 4 months in the upper jaw.¹⁹ Impressions were taken using an open-tray technique. Apolyvinylsiloxane (Express, 3 mol/L, Espe, Germany) putty and correction material was used for a one-step impression with the individual impression tray covered with adhesive. Porcelain fused to metal, fixed restorations were constructed and cemented with resin modified glass-ionomer cement (Fuji Plus; GC, Tokyo, Japan). After cementation, radiographic images were taken to ensure abutment seating and to check for residual cement (Fig 6). Patients were followed up 6 and 12 months after prosthetic treatment for oral hygiene procedures and evaluation of reconstruction. At each visit, the restorations were evaluated for mobility, peri-implant soft tissue condition

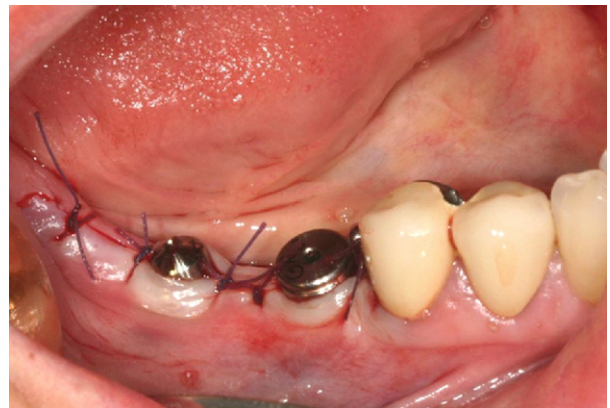

FIGURE 5. Healing abutment connected to implants.

Linkevicius et al. Crestal Bone Stability Around Implants. J Oral Maxillofac Surg 2010.

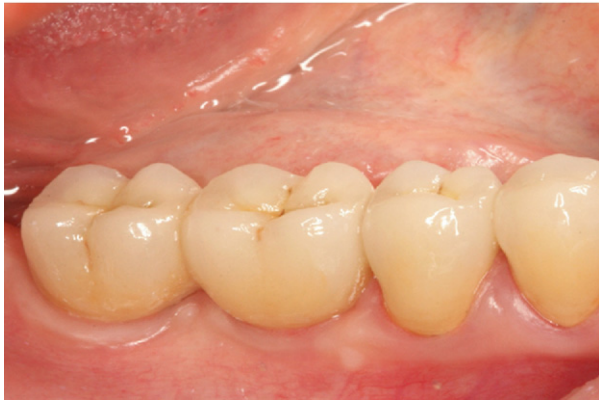

FIGURE 6. Splinted metal-ceramic restorations on test and control implants.

Linkevicius et al. Crestal Bone Stability Around Implants. J Oral Maxillofac Surg 2010.

and patient satisfaction. Intraoral radiographs were taken to evaluate bone changes.

RADIOGRAPHIC ASSESSMENT

Intraoral radiographs were taken with RVG Windows Trophy 5.0 (Trophy Radiologie Inc, Paris, France) using a paralleling technique with Rinn-like film holder in high-resolution mode. The images were obtained to ensure implant/abutment interface, and the threads were clearly visible. Before measurement, the parallelism of all intraoral radiographs was evaluated. Radiological evaluation and measurements were performed after implant placement (Fig 7) and after 10-year follow-up (Fig 8) by one of the examiners using RVG Windows Trophy 5.0 software measurement program with a calibration mode.

STATISTICAL ANALYSIS

Data were analyzed using SPSS 15.0 Windows (SPSS, Chicago, IL) statistical software. Pearson's cor-




FIGURE 7. Crestal bone level after implant placement.

Linkevicius et al. Crestal Bone Stability Around Implants. J Oral Maxillofac Surg 2010.

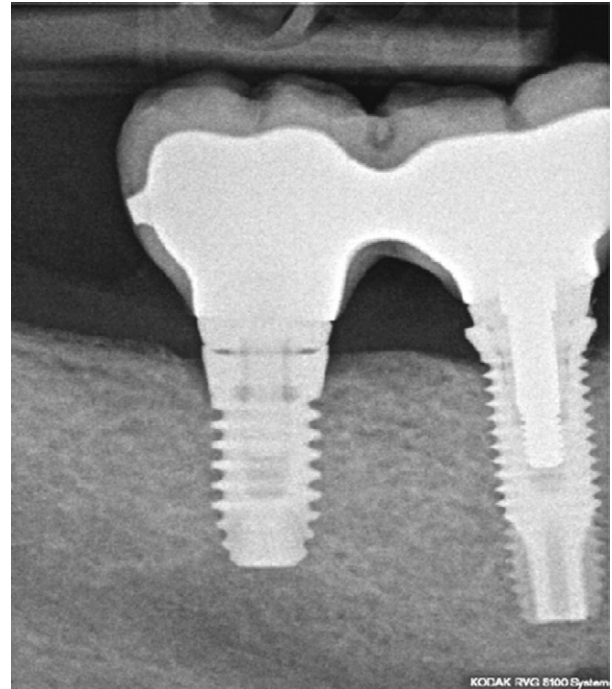


FIGURE 8. Crestal bone level after 1 year of follow-up.

Linkevicius et al. Crestal Bone Stability Around Implants. J Oral Maxillofac Surg 2010.

relation coefficient was calculated to explore the direction and strength of the relationship between medial and distal sites of the same implant. Next, analysis of variance (ANOVA) was conducted to assess mean differences between the groups. The mean differences were considered statistically significant at $P \leq .05$ with a confidence interval of 95%.

Results

All 12 implants integrated successfully and were restored with 5 splinted crowns and 1 fixed partial denture of 3 units, using metal-ceramic prostheses.

Mean \pm SD mucosal tissue thickness registered at the time of implant placement was 1.79 ± 0.25 mm (range, 1.5 to 2.0 mm). Bone loss around test implants was 1.81 ± 0.39 mm on the mesial site and 1.70 ± 0.35 mm on the distal aspect. Control implants overcame marginal bone resorption equaling 1.60 ± 0.46 mm on the mesial site and 1.76 ± 0.45 mm on the distal measurement. No statistically significant difference was found between control and test implants, either mesially ($F_{[1,10]} = 0.746$; $P = .408$) or distally ($F_{[1,10]} = 0.080$; $P = .783$).

Discussion

The results of this pilot study have shown that platform switching modification does not prevent crestal

bone loss if mucosal tissues are 2 mm or less at the top of the edentulous ridge before implant placement. Test and control implants had very similar amounts of marginal bone resorption; the differences were not statistically significant. Based on this outcome, the null hypothesis was rejected.

This conclusion is contrary to prevailing opinion that platform switching is efficient in limiting bone remodeling. Previous reports and recent publications unanimously indicate that platform switching should be used to facilitate the stability of peri-implant tissues.^{20,21} For example, Vela-Neblo et al⁶ have compared regular connection implants with platform switched implants. Implants in both groups were positioned equally with bone crest and later restored with single crowns. After 12 months of loading, the mean value of bone loss observed in the medial and distal measurements for the control group were 2.53 and 2.56 mm and for the test sample were 0.76 and 0.77 mm, respectively. This difference was found to be statistically significant and supported the recommendation to use implants with platform switching for crestal bone preservation.

This study has numerous similarities with the current pilot experiment. First, both studies used 2 types of implants, namely, platform switched and with regular implant-abutment junction. Second, in both studies, implants were placed at the bone level. Third, the follow-up period was the same. However, the major difference was the absence of a presurgical mucosal tissue thickness measurement in the Vela-Neblo et al⁶ study. Furthermore, the authors mentioned that some of the test implants had approximately 1.3-mm bone loss, but no further explanation for this was provided. It could be suggested that this unusual bone loss could have occurred because of the possible presence of thin tissue, bearing in mind that the study design did not include mucosal tissue measurement.

A similar speculation could be attributed to another clinical study, which retrospectively evaluated Ankylos (Fiadent, Mannheim, Germany) implants. It appeared that bone loss around implants with platform switching was only 0.2 mm within 3 years of loading, although bone resorption after implants uncovering ranged from 0.5 to 2 mm on average.²² Again, as initial tissue thickness before implant placement was not registered or reported, it can be assumed that bone loss up to 2 mm could be a consequence of thin tissue.

Studies by Cappiello et al,⁴ Canullo and Rasperini,²³ and Calvo-Guilardo et al²⁴ also did not describe measurements of mucosal tissue thickness before implant placement.

The results of this pilot study agree with those of a clinical trial that showed that initially thin soft tissues might be a decisive factor in causing crestal bone loss around supracrestally placed implants.¹⁸

The platform switching concept is based on the assumption that moving the implant-abutment connection away from the bone crest by connecting a prosthetic abutment of narrower diameter would reduce inflammation and, subsequently, bone resorption. The explanation for this phenomenon can be found in a study by Ericsson et al,²⁵ who detected inflammatory cell infiltrate in the connective tissue zone, contacting the implant-abutment interface of 2-piece implants with a regular connection. The authors suggested that formation of infiltrate is a defensive action of the host from a micro-gap contaminated with oral bacteria. Because in implants with platform switching the micro-gap is shifted away from bone, inflammatory cell infiltrate does not form in close proximity to bone; therefore, crestal bone loss is reduced. This hypothesis was described by Lazzarra et al²⁶ in an article based on a summary of radiographic observations of implants with platform switching from 5 to 13 years. The authors suggested that platform switching repositions inflammatory infiltrate within approximately a 90-degree-confined area of exposure, instead of a 180-degree surface of regular connection implants; thus the infiltrate is smaller around platform switched implants, which results in less bone loss.

However, the results of this pilot study indicate that the altered horizontal relationship between the outer edge of the implant and a smaller-diameter abutment does not prevent crestal bone loss if mucosal tissues at the time of implant placement are 2 mm or less. All implants in the test group, formed of implants with platform switching, overcome mean bone loss of approximately 1.76 mm, which is slightly less than in the control group implants (1.88 mm); however, this difference was not statistically significant.

It can be suggested that this bone loss occurred during biologic width formation, as the primary tissue thickness was not sufficient for a peri-implant seal to form without hard tissue resorption. It was shown that peri-implant seal needs to be approximately 4 mm in humans²⁷ to efficiently protect the osseointegrated implant from the oral environment. Thus, it is obvious that 2 mm of initial mucosal tissue thickness is not sufficient for stable peri-implant seal formation. It can be speculated that anatomical conditions such as mucosal tissue thickness may play a key role that is probably more important than the implant-abutment connection type in early crestal bone loss etiology.

Bone loss around control implants, placed equally with bone crest was obvious, as many studies have shown bone resorption around 2-piece implants with a micro-gap at the bone level.

The results of this trial should be carefully considered, as the small sample size precludes stronger conclusion formulation. The pilot study described is a

small-scale methodological test intended to ensure that proposed methods and procedures will work in practice before being applied in a large, expensive investigation. Pilot studies provide an opportunity to make adjustments and revisions before incurring the heavy costs associated with a large study.

Sample size in pilot studies is also an object of discussion. A recent pilot investigation by Schwarz et al used 8 implants placed in 4 dogs for primary evaluation of new implant design and crestal bone measurements.²⁸ Even fewer implants were tested in an animal experiment that evaluated flapless implant placement and simultaneous peri-implant defect correction, namely, 5 implants placed in 5 dogs.²⁹ In contrast, a pilot study by Shahidi et al³⁰ involved 37 patients and 54 implants to test a new papilla regeneration technique in implant dentistry. Thus, it can be considered that sample size in the current pilot study is adequate.

This pilot study suggests that platform switching of implants may not preclude early crestal bone loss if, at the time of implant placement, mucosal tissue thickness at the implantation site is 2 mm or less. Also, measurement of mucosal tissue thickness could be recommended in all studies on crestal bone loss around implants.

References

- Albrektsson T, Zarb G, Worthington P, et al: The long-term efficacy of currently used dental implants: A review and proposed criteria of success. *Int J Oral Maxillofac Implants* 1:11, 1986
- Norton MR: Biologic and mechanical stability of single-tooth implants: 4- to 7-year follow-up. *Clin Implant Dent Relat Res* 3:214, 2001
- Norton MR: Multiple single-tooth implant restorations in the posterior jaws: Maintenance of marginal bone levels with reference to the implant-abutment microgap. *Int J Oral Maxillofac Implants* 21:777, 2006
- Cappiello M, Luongo R, Di ID, et al: Evaluation of peri-implant bone loss around platform-switched implants. *Int J Periodontics Restorative Dent* 28:347, 2008
- Hurzeler M, Fickl S, Zuhr O, et al: Peri-implant bone level around implants with platform-switched abutments: Preliminary data from a prospective study. *J Oral Maxillofac Surg* 65:33, 2007
- Vela-Nebot X, Rodriguez-Ciurana X, Rodado-Alonso C, et al: Benefits of an implant platform modification technique to reduce crestal bone resorption. *Implant Dent* 15:313, 2006
- Jung RE, Jones AA, Higginbottom FL, et al: The influence of non-matching implant and abutment diameters on radiographic crestal bone levels in dogs. *J Periodontol* 79:260, 2008
- Luongo R, Traini T, Guidone PC, et al: Hard and soft tissue responses to the platform-switching technique. *Int J Periodontics Restorative Dent* 28:551, 2008
- Broggini N, McManus LM, Hermann JS, et al: Persistent acute inflammation at the implant-abutment interface. *J Dent Res* 82:232, 2003
- Hermann JS, Cochran DL, Nummikoski PV, et al: Crestal bone changes around titanium implants. A radiographic evaluation of unloaded nonsubmerged and submerged implants in the canine mandible. *J Periodontol* 68:1117, 1997
- Hermann JS, Schoolfield JD, Schenk RK, et al: Influence of the size of the microgap on crestal bone changes around titanium implants. A histometric evaluation of unloaded non-submerged implants in the canine mandible. *J Periodontol* 72:1372, 2001
- Hermann JS, Buser D, Schenk RK, et al: Biologic width around one- and two-piece titanium implants. *Clin Oral Implants Res* 12:559, 2001
- Hermann JS, Schoolfield JD, Nummikoski PV, et al: Crestal bone changes around titanium implants: A methodologic study comparing linear radiographic with histometric measurements. *Int J Oral Maxillofac Implants* 16:475, 2001
- Misch CE, Dietsch-Misch F, Hoar J, et al: A bone quality-based implant system: First year of prosthetic loading. *J Oral Implantol* 25:185, 1999
- Hammerle CH, Bragger U, Burgin W, et al: The effect of subcrestal placement of the polished surface of ITI implants on marginal soft and hard tissues. *Clin Oral Implants Res* 7:111, 1996
- Wiskott HW, Belser UC: Lack of integration of smooth titanium surfaces: A working hypothesis based on strains generated in the surrounding bone. *Clin Oral Implants Res* 10:429, 1999
- Berglundh T, Lindhe J: Dimension of the periimplant mucosa. Biological width revisited. *J Clin Periodontol* 23:971, 1996
- Linkevicius T, Apse P, Grybauskas S, et al: The influence of soft tissue thickness on crestal bone changes around implants: A 1-year prospective controlled clinical trial. *Int J Oral Maxillofac Implants* 24:712, 2009
- Esposito M, Grusovin MG, Willings M, et al: Interventions for replacing missing teeth: Different times for loading dental implants. *Cochrane Database Syst Rev* Jan 21(1):CD003878, 2009
- Canullo L, Iurlaro G, Iannello G: Double-blind randomized controlled trial study on post-extraction immediately restored implants using the switching platform concept: Soft tissue response. Preliminary report. *Clin Oral Implants Res* 20:414, 2009
- Vigolo P, Givani A: Platform-switched restorations on wide-diameter implants: A 5-year clinical prospective study. *Int J Oral Maxillofac Implants* 24:103, 2009
- Chou CT, Morris HF, Ochi S, et al: Crestal bone loss associated with the Ankylos implant: Loading to 36 months. Part II. *J Oral Implantol* 30:134, 2004
- Canullo L, Rasperini G: Preservation of peri-implant soft and hard tissues using platform switching of implants placed in immediate extraction sockets: A proof-of-concept study with 12- to 36-month follow-up. *Int J Oral Maxillofac Implants* 22:995, 2007
- Calvo Guirado JL, Ortiz Ruiz AJ, Gomez MG, et al: Immediate loading and immediate restoration in 105 expanded-platform implants via the Diem System after a 16-month follow-up period. *Med Oral Patol Oral Cir Bucal* 13:E576, 2008
- Ericsson I, Persson LG, Berglundh T, et al: Different types of inflammatory reactions in peri-implant soft tissues. *J Clin Periodontol* 22:255, 1995
- Lazzara RJ, Porter SS: Platform switching: A new concept in implant dentistry for controlling postrestorative crestal bone levels. *Int J Periodontics Restorative Dent* 26:9, 2006
- Glauser R, Schupbach P, Gottlow J, et al: Periimplant soft tissue barrier at experimental one-piece mini-implants with different surface topography in humans: A light-microscopic overview and histometric analysis. *Clin Implant Dent Relat Res* 7:S44, 2005 (suppl 1)
- Schwarz F, Herten M, Bieling K, et al: Crestal bone changes at nonsubmerged implants (Camlog) with different machined collar lengths: A histomorphometric pilot study in dogs. *Int J Oral Maxillofac Implants* 23:335, 2008
- Jeong SM, Choi BH, Li J, et al: Simultaneous flapless implant placement and peri-implant defect correction: An experimental pilot study in dogs. *J Periodontol* 79:876, 2008
- Shahidi P, Jacobson Z, Dibart S, et al: Efficacy of a new papilla generation technique in implant dentistry: A preliminary study. *Int J Oral Maxillofac Implants* 23:926, 2008