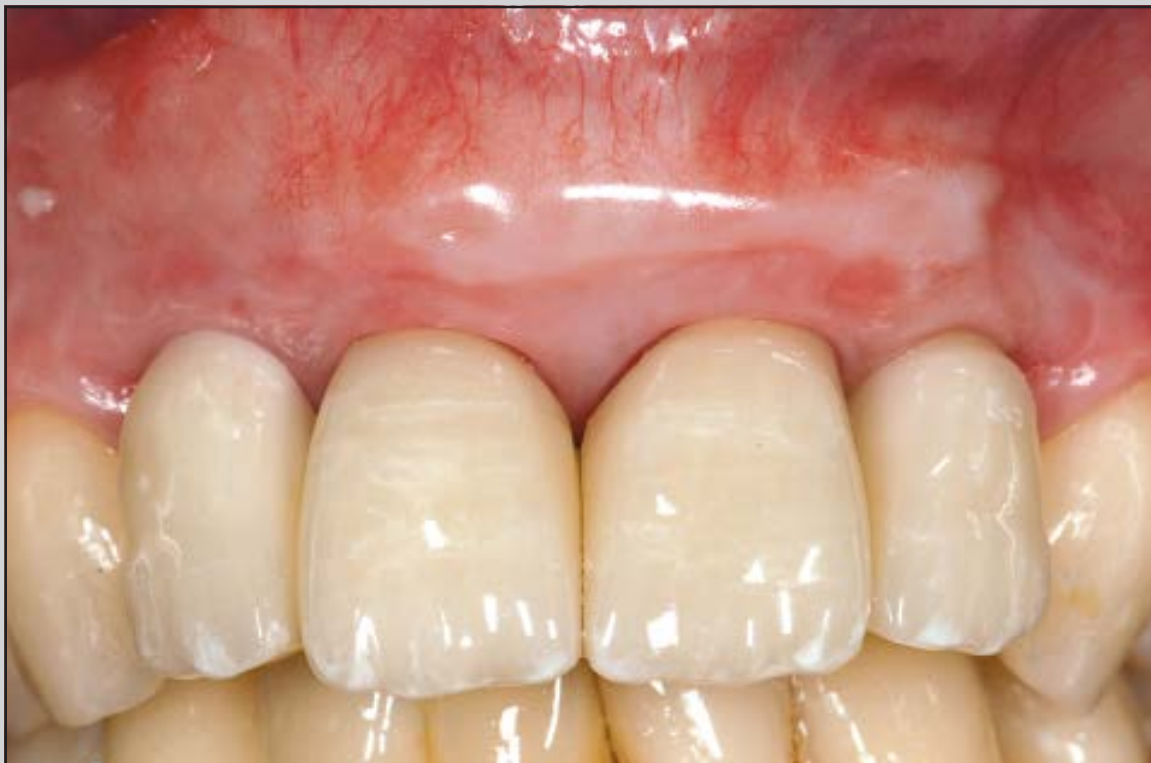
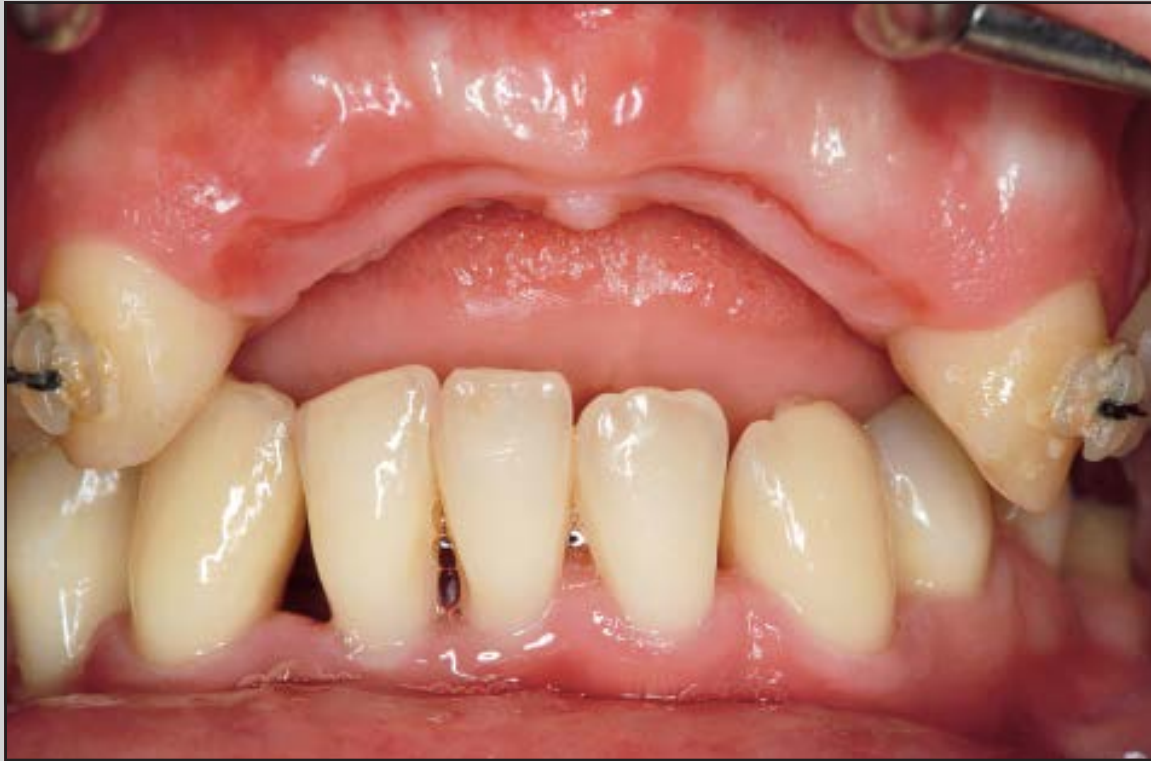
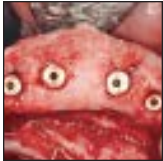

# Vertical Ridge Augmentation and Soft Tissue Reconstruction of the Anterior Atrophic Maxillae: A Case Series



Istvan A. Urban, DMD, MD, PhD<sup>1</sup>  
 Alberto Monje, DDS<sup>2</sup>  
 Jaime Lozada, DMD<sup>3</sup>  
 Hom-Lay Wang, DDS, MSD, PhD<sup>4</sup>

*Severe vertical ridge deficiency in the anterior maxilla represents one of the most challenging clinical scenarios in the bone regeneration arena. As such, a combination of vertical bone augmentation using various biomaterials and soft tissue manipulation is needed to obtain successful outcomes. The present case series describes a novel approach to overcome vertical deficiencies in the anterior atrophied maxillae by using a mixture of autologous and anorganic bovine bone. Soft tissue manipulation including, but not limited to, free soft tissue graft was used to overcome the drawbacks of vertical bone augmentation (eg, loss of vestibular depth and keratinized mucosa). By combining soft and hard tissue grafts, optimum esthetic and long-term implant prosthesis stability can be achieved and sustained. (Int J Periodontics Restorative Dent 2015;35:613–623. doi: 10.11607/prd.2481)*

An unavoidable series of events takes place after tooth extraction, often leading to vertical and horizontal ridge deficiencies.<sup>1–5</sup> Schropp et al<sup>3</sup> reported that 50% of the horizontal and 0.7-mm vertical volumetric changes occurred within the first 3 months after extraction. In a systematic review, Van der Weijden et al<sup>6</sup> showed that after all the resorptive events are over, a mean buccolingual/palatal loss of 3.87 mm and vertical reduction of 1.7 mm might result in difficulty in obtaining implant stability in the adequate positions. In addition, periodontal disease as well as trauma can lead to ridge deficiencies. Therefore, it has been suggested that these clinical difficulties might be overcome by placing shorter implants,<sup>7</sup> performing bone augmentation,<sup>8,9</sup> placing tilted implants, or using restorations with artificial gingiva as well as other approaches.<sup>10</sup>

Vertical ridge augmentation (VRA) is one way to overcome these challenges, but it remains one of the most difficult clinical procedures currently performed.<sup>11</sup> When dealing with vertical ridge deficiency, the regenerative treatment option will be based on severity. Although for slight vertical atrophy ( $\leq 3$  mm), more conservative approaches might be proposed (ie, orthodontic extrusion), for medium (4 to 6 mm) or large ( $> 7$  mm) defects, guided

<sup>1</sup>Assistant Professor, Graduate Implant Dentistry, Loma Linda University, Loma Linda, California, USA; Director, Urban Regeneration Institute, Budapest, Hungary.

<sup>2</sup>Graduate Student and Research Fellow, Graduate Periodontics, Department of Periodontics and Oral Medicine, School of Dentistry, University of Michigan, Ann Arbor, Michigan, USA.

<sup>3</sup>Professor, Department of Restorative Dentistry, and Director of Graduate Implant Dentistry, Loma Linda University, Loma Linda, California, USA.

<sup>4</sup>Professor and Director of Graduate Periodontics, Department of Periodontics and Oral Medicine, School of Dentistry, University of Michigan, Ann Arbor, Michigan, USA.

Correspondence to: Dr Istvan A. Urban, Director, Urban Regeneration Institute, Sodras utca 9, Budapest, 1026 Hungary.

Fax: +36-1-2004447. Email: Istvan@implant.hu

©2015 by Quintessence Publishing Co Inc.

bone regeneration (GBR) or onlay bone graft might be preferred.<sup>12</sup> Certainly, autogenous bone blocks have demonstrated successful VRA<sup>13</sup>: a recent systematic review reported that a mean gain of 4.75 mm vertical height can be achieved,<sup>14</sup> whereas others have pointed out that only 0.6-mm vertical bone gain can be achieved from intraoral blocks.<sup>13</sup> However, this technique is not exempt from complications, with exposure of the bone block being the most common regardless of the placement of barrier membranes.<sup>13</sup> Nevertheless, this exposure rate increased to 33% when titanium mesh was used.<sup>15</sup> Furthermore, Ozaki and Buchman<sup>16</sup> examined the resorptive pattern of block grafts for bone augmentation and found that regardless of the embryologic origin of the bone graft, an unavoidable resorption (15%–60%) might occur.<sup>13,17–19</sup> Recently, the use of allogeneic bone blocks showed some promising results; nevertheless, there is still a lack of long-term evidence supporting its utilization.<sup>20</sup> Therefore, clinicians are examining other possibilities (eg, materials and techniques). GBR using anorganic bovine bone in combination with autologous bone was shown to be effective in augmenting atrophied maxillary ridges vertically.<sup>21–23</sup> The rationale behind this mixture is that the autologous bone supplies the graft with the osteoinductive capacity and the anorganic bovine bone acts as a scaffold for space creation and maintenance.<sup>24</sup> Even though a wide range of complication rates have been reported in the literature for this approach (0%–45%),<sup>25</sup> the

local confounding factors (ie, location, morphology, or biomaterials) are yet to be determined. To predictably achieve successful bone augmentation, a PASS principle (Primary wound closure, Angiogenesis, clot Stability, and Space maintenance) should be used.<sup>26</sup> As such, when performing VRA, space creation and maintenance are essential. Nonresorbable titanium-reinforced barrier membranes fulfill the aforementioned criteria and have been suggested for large VRA.<sup>27,28</sup>

Another important factor is flap closure during bone augmentation. The key to achieving wound closure is not only the clinician's ability to obtain tension-free release flap but also good soft tissue quality and quantity. In an attempt to achieve wound closure and hence graft stability, the buccal mucosa is often broadly released, and this often results in a severe apical translocation of the mucogingival line, loss of vestibule, and keratinized mucosa (KM). When the vestibule becomes shallow, it often leads to an esthetic challenge as well as a phonetics problem. Moreover, research has shown that areas with minimal KM often have a higher peri-implant plaque accumulation, inflammation, and attachment loss.<sup>29,30</sup>

A recent systematic review demonstrated that the combination of apically positioned flap and free gingival graft (FGG) is the most successful approach to increase the width of KM and deepen the vestibule.<sup>31</sup> However, when comparing the use of epithelialized gingival grafts with free connective tissue grafts, their ability to promote KM is similar<sup>32</sup> but FGG

results in less tissue shrinkage,<sup>31</sup> which provides enhanced stability, even though the esthetic outcome is usually less favorable than that of the nonepithelialized graft.<sup>32</sup>

The purpose of this case series is to describe a novel approach that combines hard and soft tissue grafts to successfully correct severe anterior atrophic maxillae and to develop a positive gingival architecture between implants placed in vertically augmented ridges.

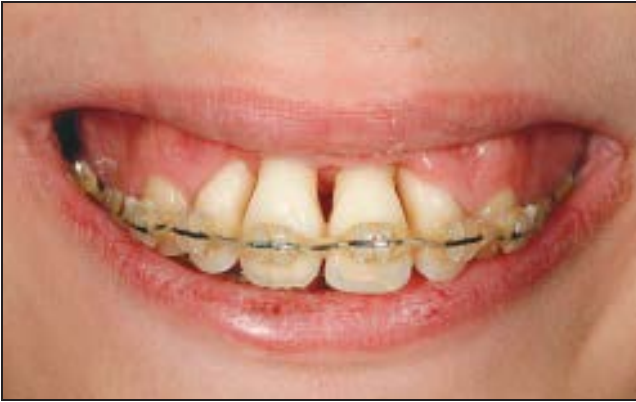## Method and materials

### *Cases included*

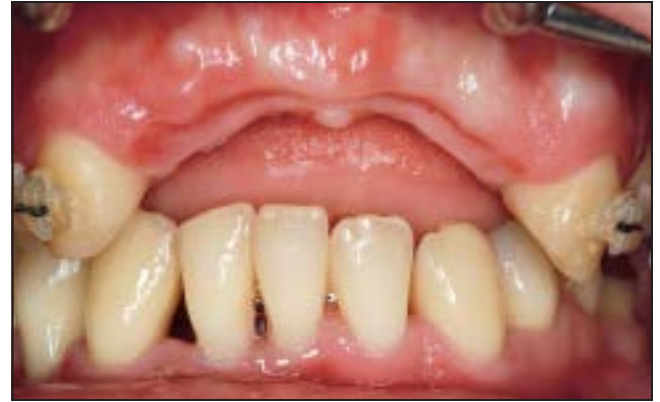Six patients (mean age: 37 years; range: 23–55 years; five women and one man) in need of bone augmentation to achieve implant placement at the ideal three-dimensional position were treated with composite bone grafts (1:1 ratio of autogenous bone and bovine hydroxyapatite) for VRA (Fig 1).

### *Supraimplant bone height*

Implant bone level was determined by parallelized periapical radiographs using the ImageJ64 program. One examiner (A.M.) performed the measurements to calculate the amount of bone height achieved beyond the implant fixture level at the different time points. The measurement recorded the distance from implant neck to the coronal-most portion of the interproximal bone level. Cohen's kappa intra- and interexaminer coefficients were used



**Fig 1a** Labial views of the anterior teeth demonstrating advanced tissue loss.



**Fig 1b** Labial view demonstrating a vertical defect after extraction of the four incisors.

(with I.U. as the second examiner) to test their reliability in 25% of the cases analyzed to ensure accuracy.

### *Surgical phases*

#### **First phase: Vertical bone augmentation**

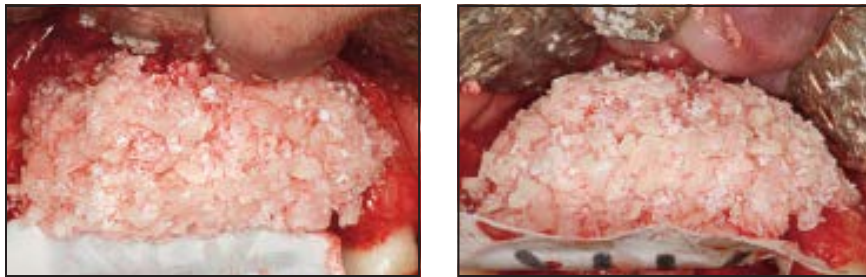
All patients were treated with VRA using a titanium-reinforced polytetrafluoroethylene (PTFE) membrane (either an expanded [e]-PTFE regenerative membrane [Gore-Tex, W.L. Gore] or dense PTFE membrane [Cytoplast Ti-250, Osteogenics Biomedical]) and a combination of autogenous bone and anorganic bovine bone-derived mineral (ABBM) (Bio-Oss, Geistlich Pharma). The medications, flap design, and sutures, and bone harvesting procedure used in this cases series have been described previously.<sup>22,23,33,34</sup> Briefly, the flap design was chosen to ensure primary tension-free

closure after the bone grafting procedure despite the increased dimension of the ridge. A remote flap procedure was performed including crestal and vertical releasing incisions. A full-thickness, midcrestal incision was made into the KM. The two divergent vertical incisions were placed at least one tooth away from the surgical site. In edentulous areas, the vertical incisions were placed at least 5 mm away from the augmentation site. After primary incisions, periosteal elevators were used to reflect a full-thickness flap beyond the mucogingival junction (MGJ) and at least 5 mm beyond the bone defect. The recipient bone bed was prepared with multiple infrabony marrow penetration using a small round bur.

The autografts were harvested and particulated in a bone mill (R. Quéting Bone-Mill, Roswitha Quéting Dental Products). A 1:1 mixture of autograft and ABBM was prepared

(referred to as *composite bone graft*) and then applied to the defect. The composite bone graft was immobilized and covered with a titanium-reinforced membrane, which was stabilized with titanium bone tacks (Master Pin Control, Meisinger) and/or titanium screws (Pro-Fix Tenting Screw, Osteogenics Biomedical) (Fig 2). Defects were measured during the grafting procedures with a calibrated periodontal probe. Vertical bone defects were measured from the most apical portion of the bony defect to a line connecting the interproximal bone height between neighboring teeth.

Once the membrane was completely secured, the flap was mobilized to permit tension-free primary closure. A periosteal releasing incision connecting the two vertical incisions was made to achieve elasticity of the flap. The releasing incision was further reinforced until a completely tension-free closure was



**Fig 2** Labial (left) and occlusal (right) views of the particulated composite bone graft.

possible. The flap was sutured in two layers: first, horizontal mattress sutures (Gore-Tex CV-5 and Cytoplast 3.0) were placed 4 mm from the incision line; then, single interrupted sutures with the same e-PTFE suture were placed to close the edges of the flap, leaving at least a 4-mm-thick connective tissue layer between the membrane and the oral epithelium. This intimate connective tissue-to-connective tissue contact provides a barrier preventing exposure of the membrane. Vertical incisions were closed with single interrupted sutures. The single interrupted sutures were removed between 10 and 14 days after surgery, and mattress sutures were removed 2 to 3 weeks later. The membrane was then removed after 9 months of healing using a full-thickness flap.

#### **Second phase: Implant placement and secondary bone graft**

Implants were placed in the correct prosthetic position using a surgical guide. The depth of implant placement corresponded to the regenerated ridge height and no implants were sunk into the newly formed bone. The implants and newly formed bone were then covered with a composite bone graft using

a 30%:70% autograft/ABBM mixture to increase the vertical height and to mimic the interproximal bone height. The goal was to increase bone thickness by 3 mm to prevent crest resorption and develop interimplant bone support for the soft tissue architecture. The graft was further covered using a collagen membrane (Bio-Gide resorbable bilayer membrane, Geistlich Pharma) and then immobilized using internal mattress sutures (6-0 polydioxanone [PDS] II, Ethicon) (Fig 3). The flaps were readapted and a primary tension-free closure was achieved. The secondary bone graft and implants were left to heal for an additional 6 months.

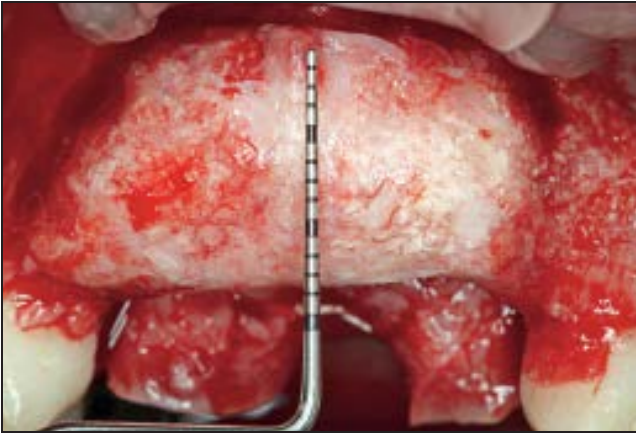#### **Third phase: Soft tissue thickening**

Two months after implant and secondary bone graft placement, a beveled floating incision was made in the KM about 0.5 mm palatal from the MGJ, which was located more palatal than the implants. The incision was of partial thickness and about 1 mm in depth. The incision involved the entire crest to 1.5 mm away from the neighboring teeth. At this point, two divergent incisions were performed at the same depth. The length of these incisions

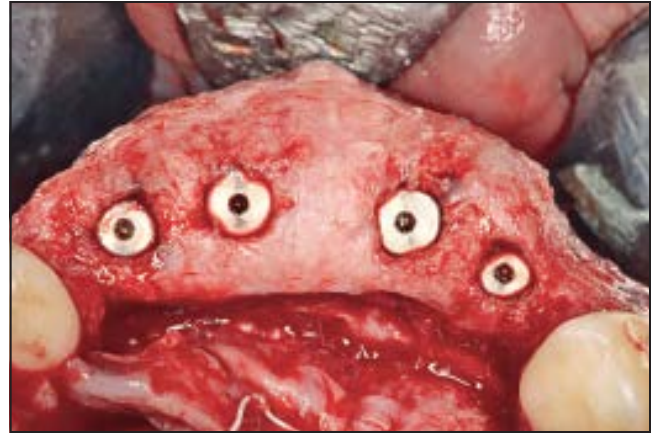was about 10 mm. Care was taken not to expose the head of the implants or the overlying bone. A sub-epithelized connective tissue graft was harvested with a single incision technique. The length of the graft occupied the entire partial-thickness flap and was about 10 mm in width. The connective tissue graft was secured with simple loop sutures and cross-mattress sutures using a resorbable monofilament suture (6-0 PDS-II) (Fig 4). The flap was then closed over the connective tissue grafts with simple interrupted sutures using a PTFE monofilament suture (Osteogenics Biomedical). Sutures were removed 2 weeks later. In the postoperative period, non-steroidal analgesics were used and no antibiotics were given.

#### **Fourth phase: Modified apically positioned flap (MAPF) and free soft tissue grafting**

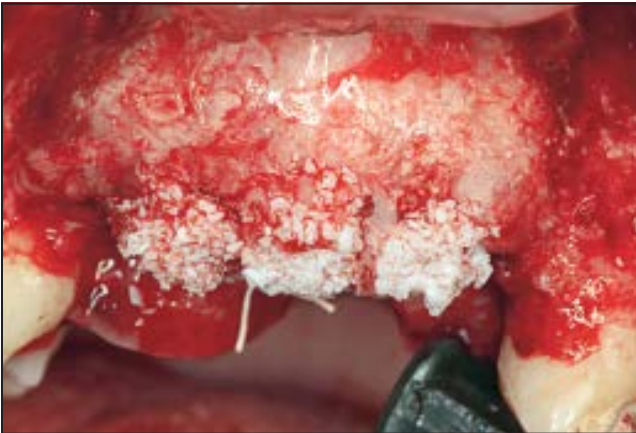Both augmentation procedures resulted in a severe loss of vestibular depth and shift of MGJ (Fig 5). The goal of the MAPF was to displace the mucosal tissue and at the same time preserve the previously transplanted connective tissue fibers over the augmented ridge. This surgical intervention was performed



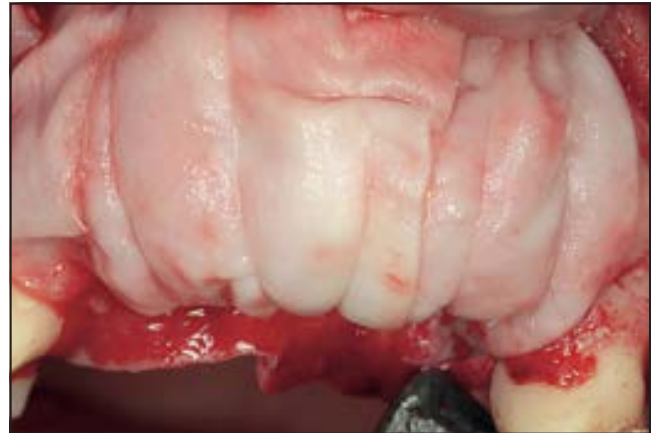**Fig 3a** (left) Labial view of the regenerated ridge after 9 months of healing.



**Fig 3b** (right) Occlusal view of implants placed in the regenerated ridge.



**Fig 3c** (left) Labial view of the supraimplant composite bone graft.



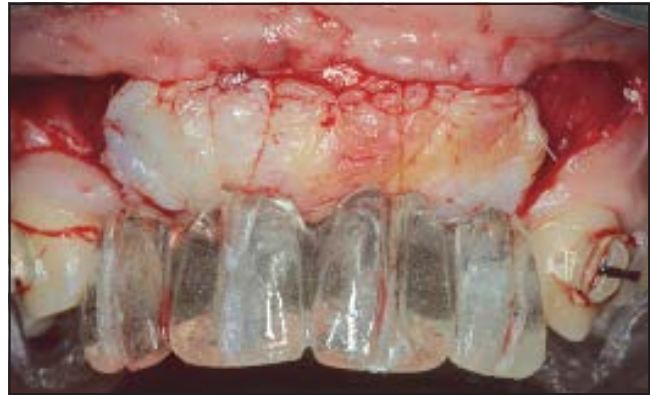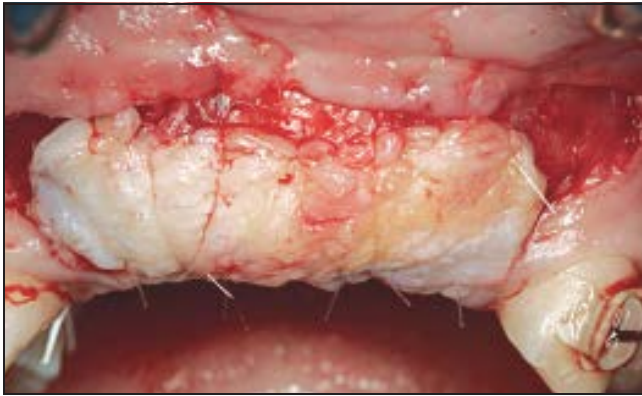**Fig 3d** (right) Labial view of the collagen membrane covering the bone graft.

6 weeks after the soft tissue thickening procedure.

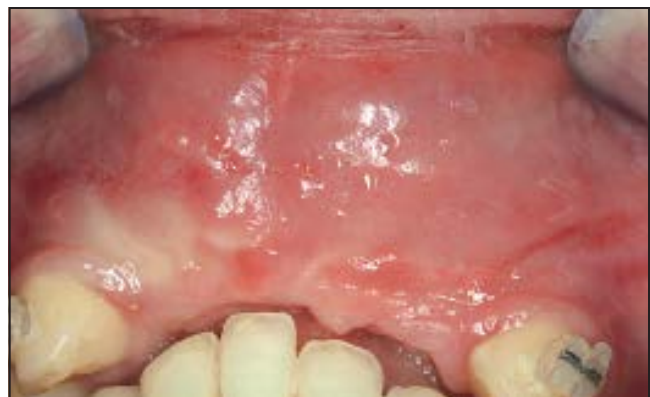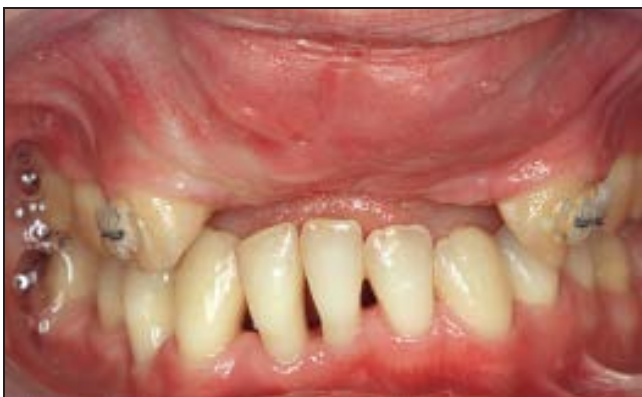The surgical intervention started with drawing a horizontal incision on KM parallel to the MGJ. The flap was then elevated with a split-thickness dissection to reposition the MGJ apically to its original position before the bone regenerative surgery and was sutured in this apical position. Two different split thicknesses were prepared and divided by regions. On top of the implants and the coronal 4 mm, only the epi-

thelium was removed and care was taken to leave the previously transplanted soft tissue fibers intact. However, after bypassing the ridge and the first 4 mm apically, a deeper preparation was started to get close to the periosteum. In this region of the recipient site, the periosteal bed was smoothed using sharp dissection to avoid any loose fibers or irregularities. An autogenous FGG of appropriate length to cover the full apical extension of the recipient gingival bed was harvested from the

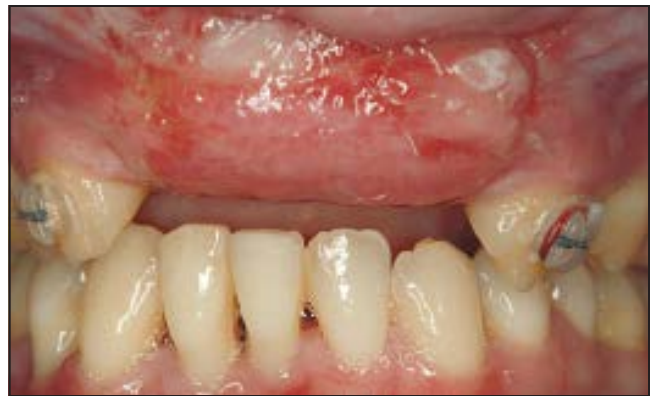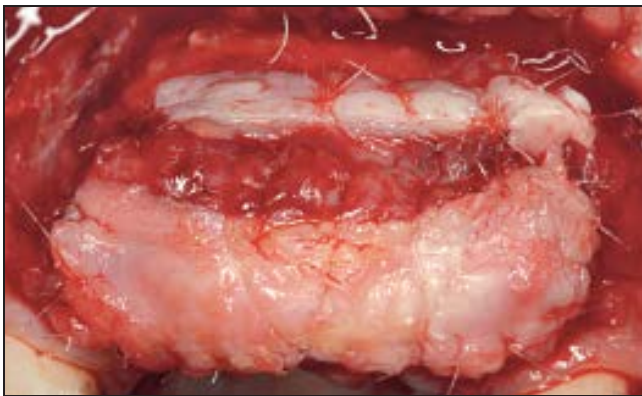
palatal mucosa. This graft was only 2 to 3 mm in width and 1 to 1.5 mm in thickness (strip graft), and was sutured immediately after its retrieval to the apical end of the recipient bed with resorbable monofilament sutures. The remainder of the periosteal bed not covered with the strip graft was covered with a free connective tissue graft and sutured in place using the same resorbable suture and techniques (Fig 6). The palatal wound was closed using 16-mm Cytoplast 3-0 mattress



**Fig 4** Labial view of the subepithelial connective tissue graft placed to increase the thickness.



**Fig 5** Labial (left) and occlusal (right) views of the mucogingival distortion.



**Fig 6a** Labial view of the combination of autogenous free connective tissue and strip gingival graft.

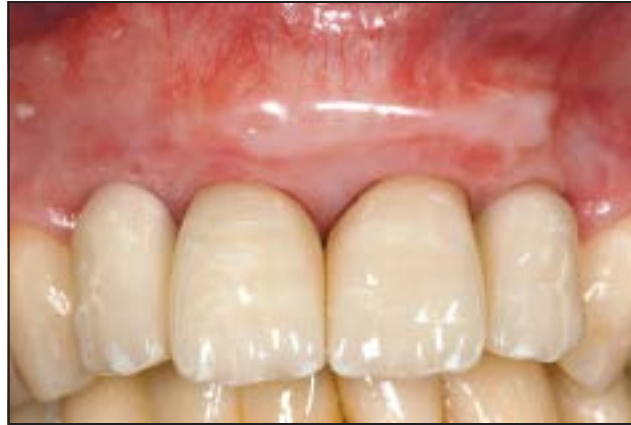**Fig 6b** Labial view of the healed soft tissue graft after 2.5 months of healing. Note the good development of vestibule, keratinized tissue, and tissue thickness.

sutures. Patients were instructed to rinse twice a day with 0.2% chlorhexidine solution (eg, Corsodyl, GlaxoSmithKline) for 1 minute. Ap-

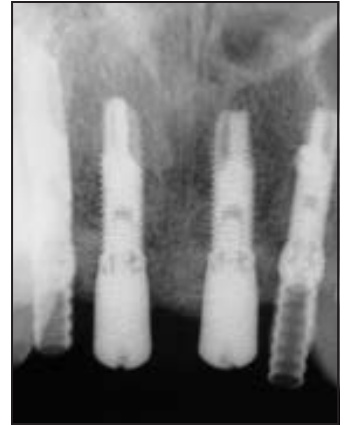propriate systemic anti-inflammatory medication (50 mg diclofenac, Cataflam, Novartis) was prescribed and patients were instructed to

comply with the prescribed regimen and return 7 and 14 days after surgery. Patients were given a fixed resin-bonded prosthesis.

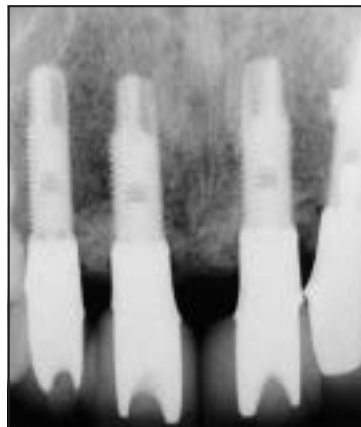
**Fig 7a** (left) Labial view of the four single implant crowns in place.



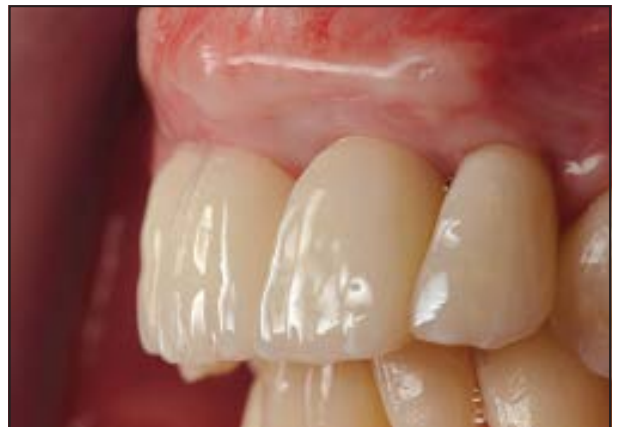**Fig 7b** (right) Periapical radiograph at uncovering of the implants. Note that customized healing abutments were used.



**Fig 7c** (left) Periapical radiograph demonstrating the stability of the supraimplant vertical bone level after 5 years of loading.



**Fig 7d** (right) Lateral clinical view of the same case. Note: Following this technique it was possible to achieve enough keratinized mucosa to maintain the peri-implant tissues under healthy conditions and to accomplish a harmonious gingival display.



**Final phase: Restorative treatment**  
After 2 months of healing, the implants were uncovered using a minimally invasive approach. Localized incisions were made above the cover screws. The bone graft above the cover screw was scraped off through the soft tissue tunnel using a microsurgical instrument. Reduced configuration healing abutments were placed and the provisional implant-supported restoration was placed within 2 weeks after the procedure. After 6 months of temporization, all-ceramic crowns were placed. Abutments were constructed to

not interfere with the bone graft in between the implants. Four years after restoration, positive soft tissue architecture of the implants was maintained after vertical augmentation in the anterior maxilla using the supraimplant grafting technique (Fig 7).

## Results

### *Vertical ridge gain before implant placement*

Healing of the bone graft was uneventful in all six patients, and all

patients achieved adequate vertical bone height with the aforementioned combination grafts to allow for proper three-dimensional implant placement. Mean VRA was 5.83 mm (max: 9 mm; min: 3mm). The VRA amount was associated with defect atrophy. In other words, the more severe the defect, the more vertical bone gain was achieved.

### *Supraimplant bone height*

Inter- and intraexaminer Cohen's kappa were 0.91 (95% confidence interval [CI] = 0.90 to 0.92) and 0.86



**Table 1** Supraimplant vertical bone gain at different time points after implant placement

Time point	No. of interimplant bone height measurements	Supraimplant bone height (mm)*
Baseline	12	2.21 ± 1.21
12 mo	9	1.20 ± 1.46
24 mo	9	1.69 ± 0.76
36 mo	7	1.40 ± 0.99
48 mo	7	1.82 ± 0.81
60 mo	3	1.72 ± 1.41
72 mo	4	1.37 ± 1.08
84 mo	3	1.39 ± 1.21

\*Mean ± standard deviation.

(95% CI = 0.84 to 0.88), respectively, indicating a high degree of reliability in the measurements. This was extracted from 18 Nobel Biocare implants (2 Nobel Replace RP CC, 1 Nobel Active RP, 11 Brånemark MKIII RP, 3 Brånemark MKIII NP, and 1 Replace Select NP). From these, an overall number of 12 interimplant bone levels (from 6 patients) were available to be measured at baseline (implants' healing abutment placement), whereas only 3 interimplant bone levels (from 2 patients) could be measured at 84 months' follow-up. Table 1 displays the mean ( $\pm$  standard deviation) supraimplant bone height values. It was noted that the mean supraimplant bone height obtained at baseline decreased significantly compared with 12-month postloading values (2.21  $\pm$  1.21 mm vs 1.20  $\pm$  1.46 mm). Nonetheless, from this point up to 84 months later, bone level changes were not significant (1.20  $\pm$  1.46 mm at baseline vs 1.39  $\pm$  1.21 mm).

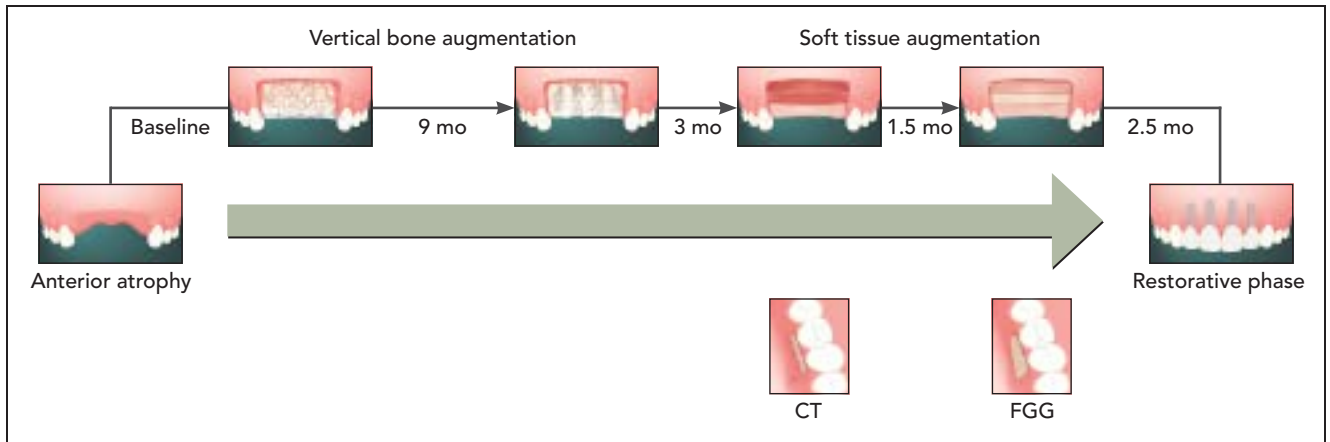
## Discussion

The case series reported herein demonstrates that a combination of VRA with GBR and soft tissue reconstructive surgery can be used to successfully reconstruct the vertically deficient anterior maxilla with an esthetically pleasing and functional result (Fig 8). With the advancement in biomaterials, GBR in the anterior maxillae is becoming a frequently performed procedure for most vertical and horizontal ridge augmentation procedures. In conjunction with the following modifications, GBR has slowly become a predictable clinical procedure in augmenting not only horizontal but also vertical bone. The mixture of autogenous bone and ABBM not only triggers the release of osteoblasts and growth factors (autogenous graft), but also acts as a space-making or maintainer (ABBM) because of its slow resorption rate.<sup>35</sup> A recently reported study has shown that ABBM

has the potential to be colonized by osteocytes CD44 positive to promote neovascularization within the particles.<sup>36</sup> This biomaterial in combination with autologous bone has also been studied for VRA using the same approach.<sup>21,22,33</sup>

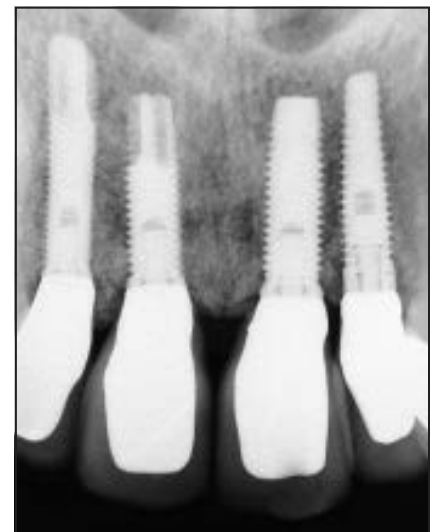
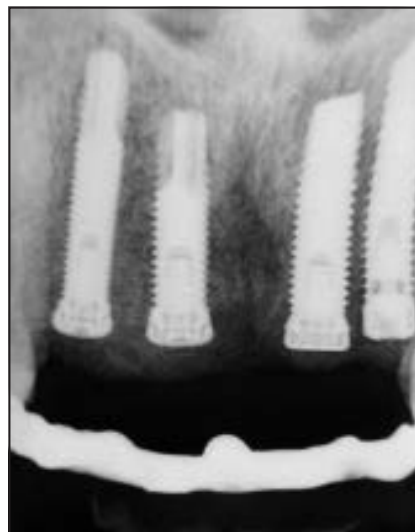In addition, Urban et al<sup>22</sup> demonstrated that under histomorphometric analysis after 8 months of graft healing, regenerated bone and newly formed bone results were 36% and 19%, respectively, whereas grafted particles were only 16%. They also showed the interconnectivity of the ABBM particles through a dense network of newly formed bone and the appearance of blood vessels. Therefore, based on clinical, radiographic, and histologic evaluation, it seems that this bone grafting mixture is a safe and predictable way to achieve vertical bone gain.

In addition, the use of titanium-reinforced PTFE membrane enables space creation as well as graft stability to avoid disruption of the osseous remodeling process.<sup>37</sup> PTFE is a synthetic fluoropolymer of tetrafluoroethylene that has been proven to be effective in excluding fibroblastlike cells from growing into the grafted defect.<sup>22,38</sup> However, the main complication of this technique is membrane exposure, documented with a wide incidence,<sup>22,23,25</sup> which may significantly jeopardize the final regenerative outcome.<sup>18</sup> In a meta-analysis, Machtei<sup>39</sup> reported that sites with membrane exposure had six times less bone gain than sites without exposure. In this regard, soft tissue characteristics then become very important to achieving complete



**Fig 8** Timeline showing the stages of VRA with GBR and soft tissue reconstructive surgery used to successfully reconstruct the vertically deficient anterior maxilla with an esthetically pleasing and functional result. CTG = connective tissue graft; FGG = free gingival graft.

**Fig 9** Representative radiographs (from case 2) of the maintenance of supraimplant bone preservation demonstrating good supraimplant stability after 84 months of loading.



and stable wound closure. Most clinicians will attempt to release/undermine the flap so the tissue can be passively moved coronally to allow for primary wound closure. Doing so allows the vestibular depth to become shallow, which then creates several challenges for patients. These include but are not limited to esthetic, phonetic, and future maintenance. The experience of the authors is that this distorted mucosal tissue is usually stretched to a

level that results in thin tissue over the regenerated crest. The aim of the tissue-thickening surgery with a connective tissue graft was to achieve the mucosal thickness necessary to establish a stable biologic width over the implants without any loss of crestal bone.<sup>40</sup> The goal was to achieve at least 4 mm of tissue thickness over the implants. However, this covered autogenous graft will not result in keratinized tissue gain as demonstrated previously.<sup>41</sup>

FGG has been shown to be the most reliable way to increase the amount of KM and vestibular deepening.<sup>42</sup> This was further confirmed by a recent systematic review, which reported that FGG remains the best documented and most successful approach to increase KM width.<sup>31</sup> FGG results in less tissue shrinkage<sup>31</sup> and enhanced stability, but it provides a less favorable esthetic outcome than the nonepithelized graft.<sup>32</sup> Hence, the authors used a

combination of an apically placed FG strip and a more crestally positioned free connective tissue graft. The combination approach was placed over a recipient bed, which was prepared according to the MAPF. This way, a thick KM was achieved, which was well attached to the recipient bed. This combination graft achieved a stable and esthetically pleasing result.

Interestingly, the mean supraimplant vertical bone height achieved in the present study was 1.5 mm. This bone height was maintained for up to 7 years despite being located above the implant-abutment interface (Fig 9). To the authors' knowledge, this is the first article to report this finding with the composite graft. More recently, a combination graft technique using a collagen matrix in combination with a strip gingival autograft was documented as a successful alternative to the entirely autogenous soft tissue grafting. This might prove to be a less invasive approach that could lead to similar KT augmentation and increased patient comfort.<sup>43</sup>

The combination of bone augmentation and soft tissue grafting resulted in a positive gingival and interimplant bone contour. If the aforementioned technique can be proven to be predictable, clinicians will have one more tool for solving the lack of interimplant papillae.

One of the major drawbacks of the proposed novel approach is the number of surgeries needed to achieve adequate hard and soft tissue support. Therefore, careful case selection is of paramount impor-

tance. The patients selected must be highly motivated and follow strict compliance with an oral hygiene regimen that is a key for successful outcomes. Although many other alternatives are described in the literature, such as block grafting or GBR without soft tissue grafting, in the present authors' experience this multiple-stage approach involves not only oral function recovery, but also excellent esthetic results that imply high patient satisfaction. To perform these procedures, significant clinical expertise is required to avoid surgical complications and obtain successful results. Hence, clinicians who perform these procedures should have adequate training and understanding of bone graft as well as soft tissue behavior. The results described herein should be confirmed in multicenter studies of larger patient populations before this becomes routine clinical treatment.

## Conclusion

By combining soft and vertical hard tissue augmentation, an optimally esthetic and functionally stable implant-supported fixed prosthesis can be achieved in the severe anterior atrophic maxillae. In addition, using the mixture of anorganic bovine bone and autologous bone, supraimplant bone gain can be successfully achieved to support future interimplant papillae formation. Nonetheless, future randomized controlled clinical trials are needed to verify the treatment approach described herein.

## Acknowledgments

This study was partially supported by the University of Michigan Periodontal Graduate Student Research Fund. We thank Stephanie O'Neill (School of Dentistry, University of Michigan) for developing the timeline included in Fig 8.

Both Drs Urban and Wang have received honoraria from Osteogenics Biomedical. Dr Urban has also received an honorarium from Geistlich Pharma and Osteogenics Biomaterials. Dr Monje has no financial interests, either directly or indirectly, in the products or information listed in this article.

## References

1. Carlsson GE. Changes in the jaws and facial profile after extractions and prosthetic treatment. *Trans R Sch Dent Stockh Umea* 1967;12:1–29.
2. Carlsson GE, Ragnarson N, Astrand P. Changes in height of the alveolar process in edentulous segments. A longitudinal clinical and radiographic study of full upper denture cases with residual lower anteriors. *Odontol Tidskr* 1967; 75:193–208.
3. Schropp L, Wenzel A, Kostopoulos L, Karring T. Bone healing and soft tissue contour changes following single-tooth extraction: A clinical and radiographic 12-month prospective study. *Int J Periodontics Restorative Dent* 2003;23: 313–323.
4. Pietrokovski J, Massler M. Residual ridge remodeling after tooth extraction in monkeys. *J Prosthet Dent* 1971;26: 119–129.
5. Pietrokovski J, Massler M. Ridge remodeling after tooth extraction in rats. *J Dent Res* 1967;46:222–231.
6. Van der Weijden F, Dell'Acqua F, Slot DE. Alveolar bone dimensional changes of post-extraction sockets in humans: A systematic review. *J Clin Periodontol* 2009;36:1048–1058.
7. Garaicoa-Pazmino C, Suarez-Lopez Del Amo F, Monje A, et al. Influence of crown/implant ratio on marginal bone loss: A systematic review. *J Periodontol* 2014;85:1214–1221.

8. Tonetti MS, Hammerle CH, European Workshop on Periodontology Group C. Advances in bone augmentation to enable dental implant placement: Consensus report of the sixth European workshop on periodontology. *J Clin Periodontol* 2008;35:168–172.
9. Hammerle CH, Jung RE. Bone augmentation by means of barrier membranes. *Periodontol* 2000. 2003;33:36–53.
10. Melcher AH. On the repair potential of periodontal tissues. *J Periodontol* 1976; 47:256–260.
11. Bernstein S, Cooke J, Fotek P, Wang HL. Vertical bone augmentation: Where are we now? *Implant Dent* 2006;15:219–228.
12. Wang HL, Al-Shammari K. HVC ridge deficiency classification: A therapeutically oriented classification. *Int J Periodontics Restorative Dent* 2002;22:335–343.
13. Chiapasco M, Zaniboni M, Rimondini L. Autogenous onlay bone grafts vs alveolar distraction osteogenesis for the correction of vertically deficient edentulous ridges: A 2–4-year prospective study on humans. *Clin Oral Implants Res* 2007;18:432–440.
14. Milinkovic I, Cordaro L. Are there specific indications for the different alveolar bone augmentation procedures for implant placement? A systematic review. *Int J Oral Maxillofac Surg* 2014;43:606–625.
15. Rocuzzo M, Ramieri G, Bunino M, Berone S. Autogenous bone graft alone or associated with titanium mesh for vertical alveolar ridge augmentation: a controlled clinical trial. *Clin Oral Implants Res* 2007;18:286–294.
16. Ozaki W, Buchman SR. Volume maintenance of onlay bone grafts in the craniofacial skeleton: Micro-architecture versus embryologic origin. *Plast Reconstr Surg* 1998;102:291–299.
17. Widmark G, Andersson B, Ivanoff CJ. Mandibular bone graft in the anterior maxilla for single-tooth implants. Presentation of surgical method. *Int J Oral Maxillofac Surg* 1997;26:106–109.
18. Chiapasco M, Zaniboni M, Boisco M. Augmentation procedures for the rehabilitation of deficient edentulous ridges with oral implants. *Clin Oral Implants Res* 2006;17 Suppl 2:136–159.
19. Monje A, Monje F, Hernandez-Alfaro F, et al. Horizontal bone augmentation using autogenous block grafts and particulate xenograft in the severe atrophic maxillary anterior ridges. *J Oral Implantol* 2014 [epub ahead of print].
20. Nissan J, Mardinger O, Calderon S, Romanos GE, Chaushu G. Cancellous bone block allografts for the augmentation of the anterior atrophic maxilla. *Clin Implant Dent Relat Res* 2011;13:104–111.
21. Urban I, Caplanis N, Lozada JL. Simultaneous vertical guided bone regeneration and guided tissue regeneration in the posterior maxilla using recombinant human platelet-derived growth factor: A case report. *J Oral Implantol* 2009; 35:251–256.
22. Urban IA, Jovanovic SA, Lozada JL. Vertical ridge augmentation using guided bone regeneration (GBR) in three clinical scenarios prior to implant placement: A retrospective study of 35 patients 12 to 72 months after loading. *Int J Oral Maxillofac Implants* 2009;24:502–510.
23. Urban IA, Lozada JL, Jovanovic SA, Nagursky H, Nagy K. Vertical ridge augmentation with titanium-reinforced, dense-PTFE membranes and a combination of particulated autogenous bone and anorganic bovine bone-derived mineral: A prospective case series in 19 patients. *Int J Oral Maxillofac Implants* 2014; 29:185–193.
24. McAllister BS, Haghighat K. Bone augmentation techniques. *J Periodontol* 2007;78:377–396.
25. Rocchietta I, Fontana F, Simion M. Clinical outcomes of vertical bone augmentation to enable dental implant placement: A systematic review. *J Clin Periodontol* 2008;35:203–215.
26. Wang HL, Boyapati L. “PASS” principles for predictable bone regeneration. *Implant Dent* 2006;15:8–17.
27. Merli M, Moscatelli M, Mariotti G, et al. Bone level variation after vertical ridge augmentation: Resorbable barriers versus titanium-reinforced barriers. A 6-year double-blind randomized clinical trial. *Int J Oral Maxillofac Implants* 2014;29:905–913.
28. Ronda M, Rebaudi A, Torelli L, Stacchi C. Expanded vs dense polytetrafluoroethylene membranes in vertical ridge augmentation around dental implants: A prospective randomized controlled clinical trial. *Clin Oral Implants Res* 2014;25:859–866.
29. Lin GH, Chan HL, Wang HL. The significance of keratinized mucosa on implant health: A systematic review. *J Periodontol* 2013;84:1755–1767.
30. Gobbato L, Avila-Ortiz G, Sohrabi K, Wang CW, Karimbux N. The effect of keratinized mucosa width on peri-implant health: A systematic review. *Int J Oral Maxillofac Implants* 2013;28:1536–1545.
31. Thoma DS, Buranawat B, Hammerle CH, Held U, Jung RE. Efficacy of soft tissue augmentation around dental implants and in partially edentulous areas: A systematic review. *J Clin Periodontol* 2014;41 Suppl 15:S77–S91.
32. Orsini M, Orsini G, Benlloch D, et al. Esthetic and dimensional evaluation of free connective tissue grafts in prosthetically treated patients: A 1-year clinical study. *J Periodontol* 2004;75:470–477.
33. Urban IA, Lozada JL. A prospective study of implants placed in augmented sinuses with minimal and moderate residual crestal bone: Results after 1 to 5 years. *Int J Oral Maxillofac Implants* 2010;25:1203–1212.
34. Urban IA, Lozada JL, Jovanovic SA, Nagy K. Horizontal guided bone regeneration in the posterior maxilla using recombinant human platelet-derived growth factor: A case report. *Int J Periodontics Restorative Dent* 2013;33:421–425.
35. Galindo-Moreno P, Hernández-Cortés P, Mesa F, et al. Slow resorption of anorganic bovine bone by osteoclasts in maxillary sinus augmentation. *Clin Implant Dent Relat Res* 2013;15:858–866.
36. Galindo-Moreno P, Hernández-Cortés P, Aneiros-Fernández J, et al. Morphological evidences of Bio-Oss(R) colonization by CD44-positive cells. *Clin Oral Implants Res* 2014;25:366–371.
37. Khojasteh A, Soheilifar S, Mohajerani H, Nowzari H. The effectiveness of barrier membranes on bone regeneration in localized bony defects: A systematic review. *Int J Oral Maxillofac Implants* 2013;28:1076–1089.
38. Simion M, Trisi P, Piattelli A. Vertical ridge augmentation using a membrane technique associated with osseointegrated implants. *Int J Periodontics Restorative Dent* 1994;14:496–511.
39. Machtei EE. The effect of membrane exposure on the outcome of regenerative procedures in humans: A meta-analysis. *J Periodontol* 2001;72:512–516.
40. Berglundh T, Lindhe J. Dimension of the periimplant mucosa. Biological width revisited. *J Clin Periodontol* 1996;23: 971–973.
41. Pini Prato GP, Clauser C, Bertelli E, Agudio G, Cortellini P. [Clinical indications for the use of free autogenous grafts of keratinized fibromucosa of the mouth. I: Periodontal indications [in Italian]. *G Stomatol Ortognatodonzia* 1983;2:45–50.
42. Sullivan HC, Atkins JH. Free autogenous gingival grafts. I. Principles of successful grafting. *Periodontics* 1968;6:121–129.
43. Urban IA, Lozada JL, Nagy K, Sanz M. Treatment of severe mucogingival defects with a combination of strip gingival grafts and a xenogeneic collagen matrix: A prospective case series study. *Int J Periodontics Restorative Dent* 2015; 35:345–353.